

# A CASE REPORT- AYURVEDIC MANAGMENT OF PILONIDAL SINUS BY USING UDUMBER KSHEERASUTRA.

*Dr. Rameshwar Khedkar <sup>1</sup>, Dr.Gaytri Mawale <sup>2</sup>*

<sup>1</sup> PG Scholar, Shalyatantra Department, Gramin Ayurved Mahavidyalaya, Patur, Akola

<sup>2</sup> HOD & Associate Professor, Shalyatantra Department, Gramin Ayurved Mahavidyalaya, Patur, Akola.

## ABSTRACT

*A Pilonidal Sinus is located in the cleavage between the buttocks (natal cleft) containing hairs and unhealthy diseased granulation tissue. It is due to penetration of hairs through the skin into subcutaneous tissue. It forms granuloma/unhealthy granulation tissue in the deeper plane. It is more common in males and mostly affects hairy men. According to Ayurveda, it is associated with Shalyajanya Nadivrana (Pilonidal Sinus), a form of Nadivrana (sinus). The etiology of which is addressed in Nidanasthana and the therapy aspect in Chikitsasthana of Sushruta Samhita using minimally invasive Parasurgical treatment like Ksheerasutra (seton) procedure to regulate Nadivrana. Although many surgical techniques have been documented in contemporary medical science, but the surgery is costly and the patient needs a longer stay in the hospital. Treatment with Ksheersutra not only reduces complications and recurrence but also speeds recovery and eases the patient's return to work and is less expensive.*

**Keyword:** Ksheersutra, Nadi Vrana Chikitsa, Pilonidal sinus, Shalya Tantra.

## 1. INTRODUCTION

The term pilonidal sinus originates from Greek and means “nest of hairs.” It is an acquired condition, most commonly seen in men with body hair. In this disorder, hair follicles are not visible within the sinus wall. Due to friction and vibration, hairs become dislodged and accumulate in the gluteal cleft, eventually entering the openings of sweat glands. The resulting sinus tract typically runs vertically between the buttocks. A similar condition is described in the Sushruta Samhita as Shalyaja Nadivrana. This ailment involves the presence of a foreign object—such as hair—embedded within the tract, leading to continuous pain and discharge caused by the accumulation of pus, dead tissue, and other debris. The resemblance between pilonidal sinus and Shalyaja Nadivrana is therefore quite evident. To address this condition, Sushruta developed a unique and minimally invasive treatment known as Ksharsutra therapy for Nadivrana. This approach not only reduces the risk of complications and recurrence but also facilitates an earlier return to daily activities. Sushruta developed a unique and minimally invasive treatment known as Ksharsutra for managing Nadivrana. This approach not only reduces complications and chances of recurrence but also promotes quicker recovery and return to daily activities.

## 2. MATERIALS AND METHODS:

A 19 yr old male patient present with complaints of pain and pus discharge from low back region between the buttocks since 2 month . Initially he noticed mild swelling at natal cleft with intermittent dull aching pain which was there for two week. Later he noticed pus discharge associated with mild itching in that area. He feel discomfort during sitting and bending. He neglected it even though it used to interfere with his daily activities. Whenever there was little injury to the area, pain and bleeding was noticed for which he consulted local physician to get rid of pain. Again he noticed mild swelling in natal cleft with intermittent dull aching pain and pus discharge since two weeks. symptoms used to aggravate by travelling on his bike and profuse sweating. For the above said complaints he consulted our opd in Gramin ayurved mahavidyalaya and college on 15 nov 2025.

### Physical Examination:

B.P:130/88 mm of Hg. P.R: 68/min. Temp: 99.5°F.  
General Survey: Appearance: Normosthaenic  
Facies: Normal Attitude: Conscious.

### Systemic Examination:

CVS: S1, S2 heard. No added sounds. CNS: NAD. RS: NAD.

### Specific Examination:

Inspection: Swelling just above the anal cleft and External opening seen at midline of anal cleft with discharging pus.

### Palpation:

Pain and localized tenderness.

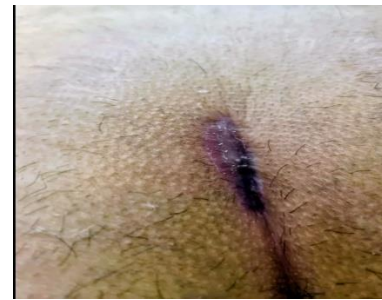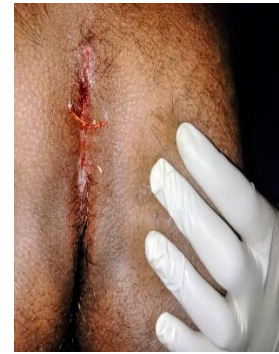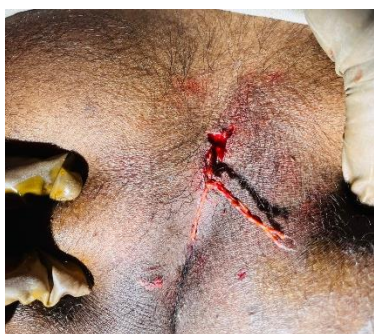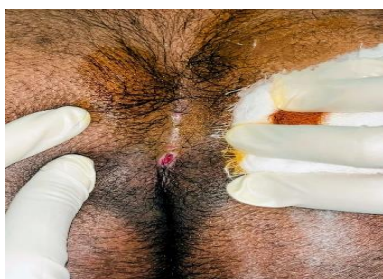
Probing: Probe was passing anteriorly into the tract.

### Investigation:

CBC: Mild leucocytosis Blood sugar: Normal HIV 1 & 2: Negative HbSAg: Negative

### 3. TREATMENT:

The area is cleaned and prepared with antiseptic solutions. Local anesthesia may be used to numb the area. A thin probe is inserted into the sinus tract to assess its depth and direction. A specially prepared Udumbara Ksheersutra thread (made from alkali-treated linen) is cut to the required length. The Udumbara Ksheersutra thread is inserted into the sinus tract through the probe. The Udumbara Ksheersutra is fixed in place with a knot. The patient is advised to return for regular weekly follow-up visits for ksheersutra changes and wound care.



### 4. DISCUSSION:

Ksharsutra is a medicated caustic thread prepared by coating it with herbal alkaline substances latex of *Ficus racemosa* (Udumber), which acts as a natural binding agent. This medicated coating not only provides local antifungal, antibacterial, and anti-inflammatory effects but also facilitates the debridement of necrotic tissue and encourages the growth of healthy granulation tissue, promoting effective healing.

Pilonidal sinus categorized under shalyajanadi vrana, can cause significant discomfort and recurrence. kshara sutra therapy is highly effective treatment modality for pilonidal sinus. It avoids the need for hospitalization and has minimal recurrence when combined with lifestyle and hygiene practices.

### 5. RESULT:

The patient has faithfully adhered to the directions. The discomfort was noticeably reduced after the 14th day; however, There was a copious serous discharge during the first two weeks, but it gradually subsides when the tract was sliced by the Udumber Ksheer Sutra. After the 28th day, there was no pus leakage. The tract was cut through on the 49th day and had a starting length of 6 cm. there after "cutting through." At the 49th day, all symptoms were completely alleviated.